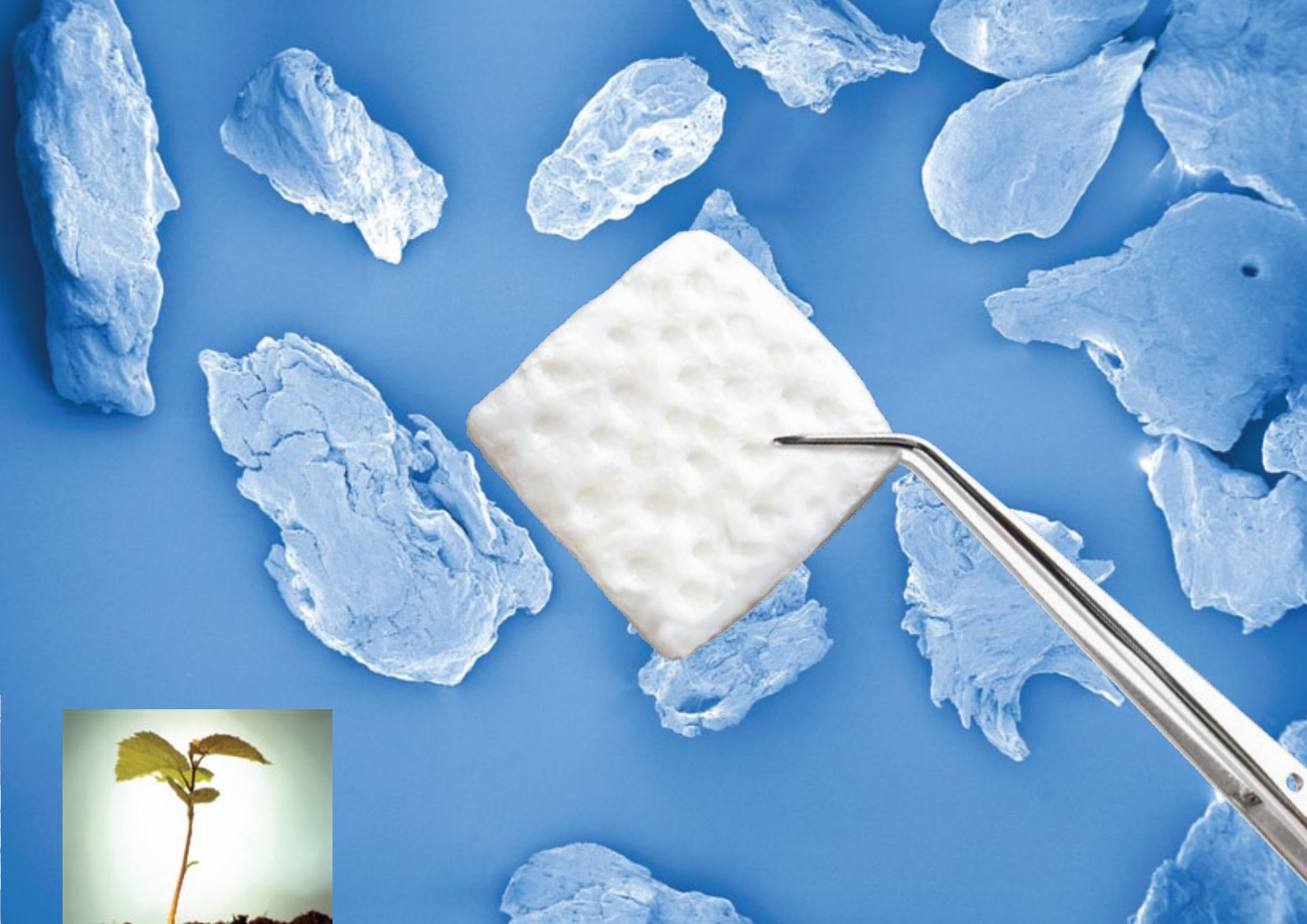



OsteoBiol[®]
by Tecnos

Derma

A XENOGENIC GRAFT FOR
SOFT TISSUE AUGMENTATION


Collagenated porcine dermal matrix

REGENERATION SCIENCE

INSPIRED BY NATURE



A xenogenic graft for soft tissue augmentation



CHARACTERISTICS

Obtained from derma of porcine origin, using an exclusive Tecnos[®] process, *Derma* membranes are gradually integrated with the autologous soft tissues⁽¹⁾. Their strong consistency and resistance allow a perfect stabilization and a prolonged protection of underlying graft in large regeneration procedures, together with a strong barrier action to guide the growth of epithelium and preventing its invagination.

HANDLING

Derma membrane can be shaped with scissors until the desired size is reached; then it must be hydrated for 5 minutes in sterile lukewarm physiological solution. Once it acquires the desired plasticity, it must be adapted to the grafting site. It is always recommendable to prepare a pocket with an elevator in order to stabilize the membrane in the site after stitching the flaps.

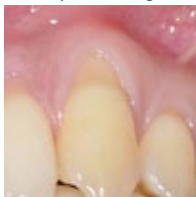CLINICAL INDICATIONS

Graft protection: *Derma* membrane is a collagen resorbable barrier to protect and stabilize bone grafting materials; only in this specific indication it can be used also in open healing situations due to its perfect tissue integration characteristics.

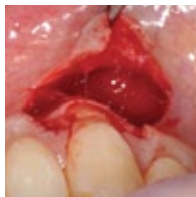Soft tissue improvement: if a residual band of keratinized tissue is still present around teeth or implants, *Derma* membrane can be used as an alternative to connective tissue graft to improve the quality of keratinized tissue.

Gingival recessions: mild gingival recessions⁽²⁾ can be treated with *Derma* to avoid patient morbidity and discomfort due to connective tissue graft harvesting. It is recommended to leave *Derma* membrane completely covered by the coronally advanced flap and to avoid membrane exposure. A properly shaped *Derma* membrane with rounded edges is also indicated for the tunnel technique.

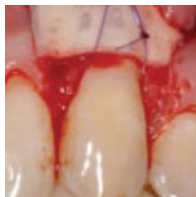Courtesy of Dr. Magda Mensi



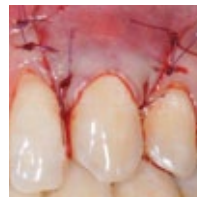Miller Class I recession



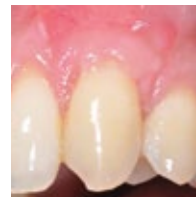Partial thickness flap



Derma grafted



Coronally advanced flap



Healing after 4 weeks

1 | Fickl S, Nannmark U, Schlagenhaut U, Hürzeler M, Kepschull M
Porcine dermal matrix in the treatment of dehiscence-type defects - an experimental split-mouth animal trial
Clinical Oral Implants Research, 2014 Feb 19. Epub ahead of print

2 | Fickl S, Jockel-Schneider Y, Lincke T, Bechtold M, Fischer KR, Schlagenhaut U
Porcine dermal matrix for covering of recession type defects: A case series
Quintessence International, 2013;44(3):243-6

Tissue of origin

Porcine derma

Tissue collagen

Preserved

Physical form

Dried membrane

Composition

100% derma

Thickness

Fine: ≈ 0.8-1.0 mm

Standard: ≈ 1.8-2.2 mm

Estimated resorption time

Fine: about 3 months

Standard: about 4 months

Packaging

Fine: 25x25 mm

Standard: 7x5 mm, 15x5 mm,

30x30 mm

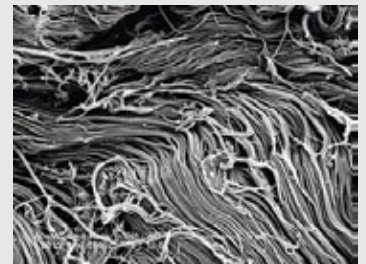
Product codes

ED25FS | Fine | 25x25 mm | Porcine

ED03SS | Std | 30x30 mm | Porcine

ED75SS | Std | 7x5 mm | Porcine

ED15SS | Std | 15x5 mm | Porcine

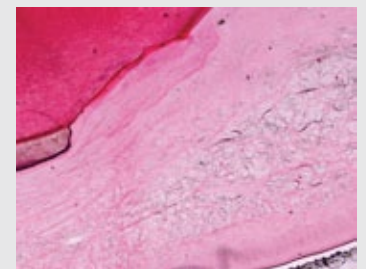


SEM image of *Derma* collagen fibers

Courtesy of Dr. Kai R. Fischer

Department of Periodontology

University Witten/Herdecke, Germany



Mucosal/gingival biopsy after 4 months.

There are no signs of inflammation and it is obvious that the thickness is kept as anticipated. Thin dark lines are remnants of the *Derma* membrane.

Htx-eosine staining. Orig mag x20.

Courtesy of Prof. Ulf Nannmark and Prof. Stefan Fickl

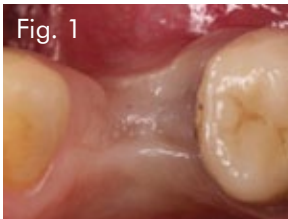

Fig. 1

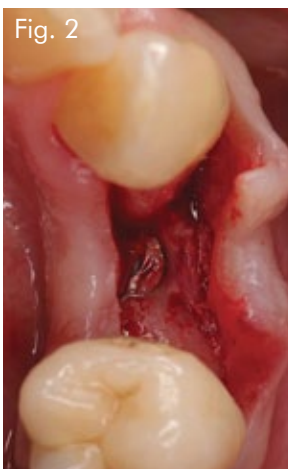

Fig. 2

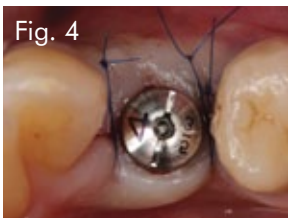


Fig. 4

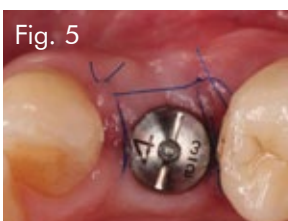

Fig. 5

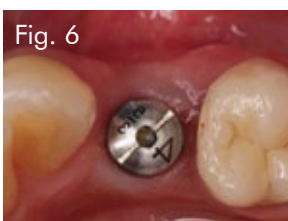

Fig. 6

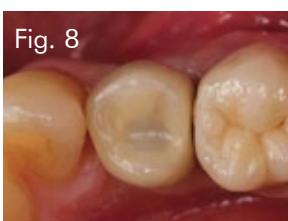

Fig. 8

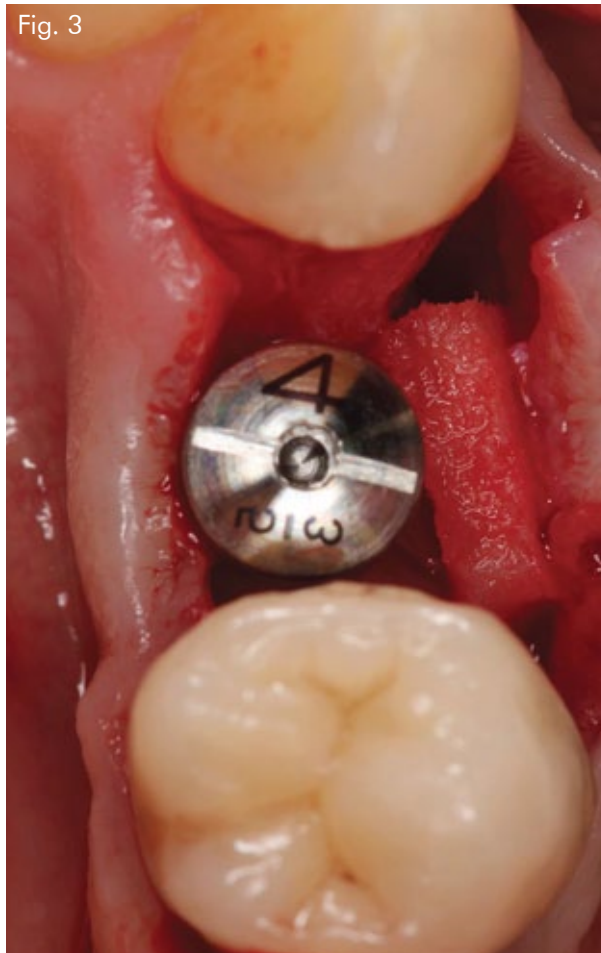

Fig. 3

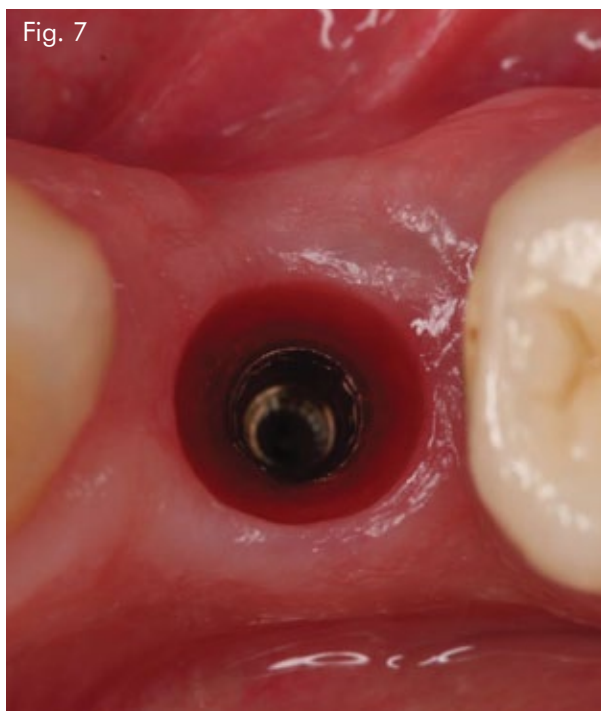


Fig. 7

CASE REPORT

Increasing tissue volume at second stage

Sex: **Female** | Age: **65**

Fig. 1 At time of second stage a volume deficit is clearly visible

Fig. 2 Following a crestal incision, the implant is exposed

Fig. 3 A pouch is obtained on the buccal aspect and *Derma* is placed

Fig. 4 Two double interrupted sutures are used to close the tissue around the healing abutment

Fig. 5 Healing after 7 days presents uneventful

Fig. 6 At time of final impression an increase of tissue volume is visible

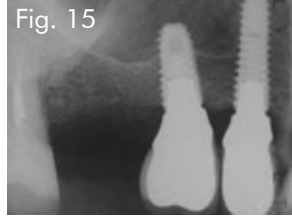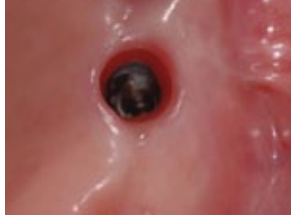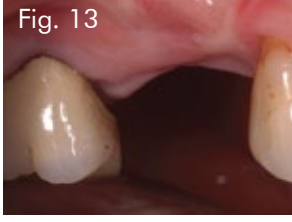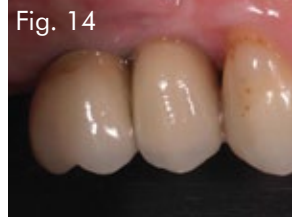
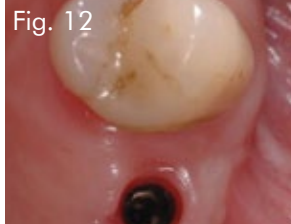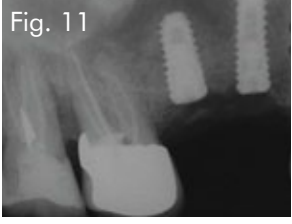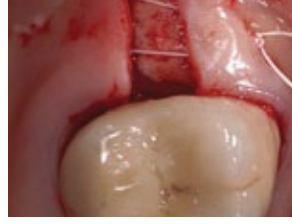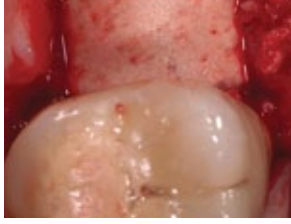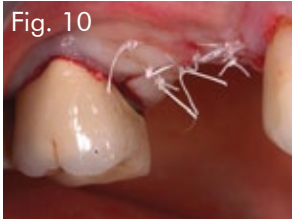
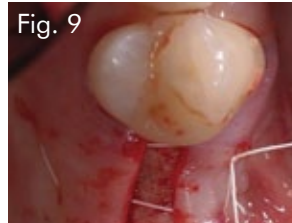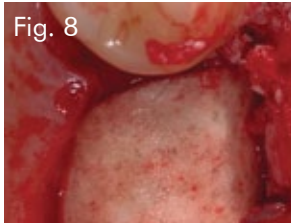
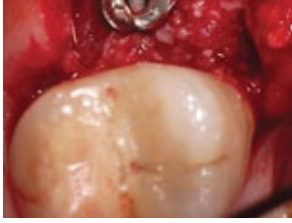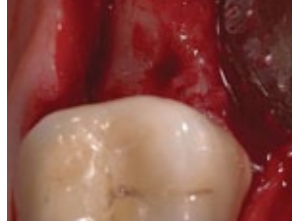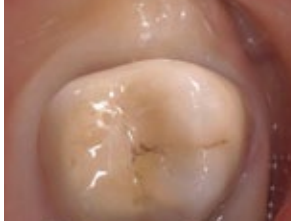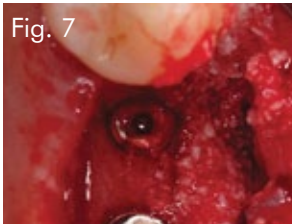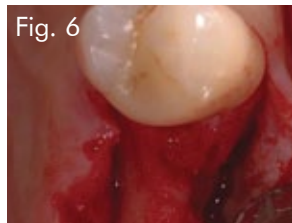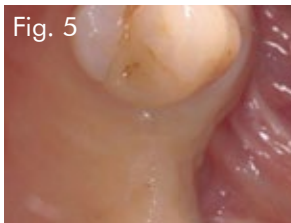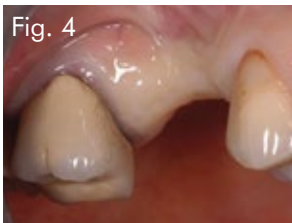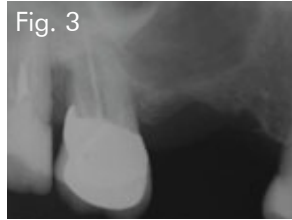
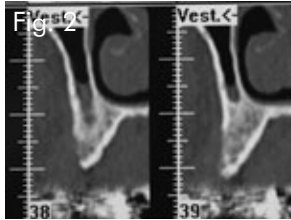
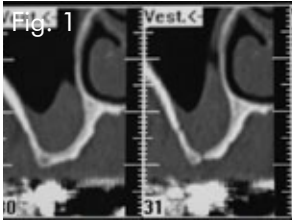
Fig. 7 Occlusal view showing that the dermal matrix is clinically fully integrated into the surrounding tissue

Fig. 8 Final reconstruction with a screw retained prosthesis

Documentation provided by
Prof **Stefan Fickl**

Priv.-Doz Dr Med Dent, Associate Professor,
Department of Periodontology,
Julius-Maximilians-University, Würzburg,
Germany

Membrane: **OsteoBio!® Derma**



CASE REPORT

Horizontal and vertical augmentation with bone graft and *Derma*

Sex: **Female** | Age: **55**

Fig. 1 Initial CT scan

Fig. 2 Initial CT scan

Fig. 3 Pre-op x-rays

Fig. 4 Clinical situation

Fig. 5 Occlusal view

Fig. 6 Bone anatomy

Fig. 7 Implants inserted and graft with mp3

Fig. 8 OsteoBioL® *Derma* grafted

Fig. 9 Horizontal mattress stitch

Fig. 10 Sutured flaps

Fig. 11 Post-op x-rays

Fig. 12 Peri-implant tissues at 12 months

Fig. 13 Vestibular view

Fig. 14 Single crowns

Fig. 15 Control x-rays

Documentation provided by

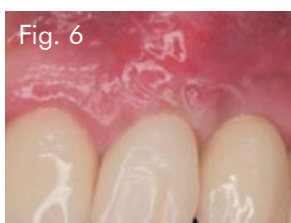
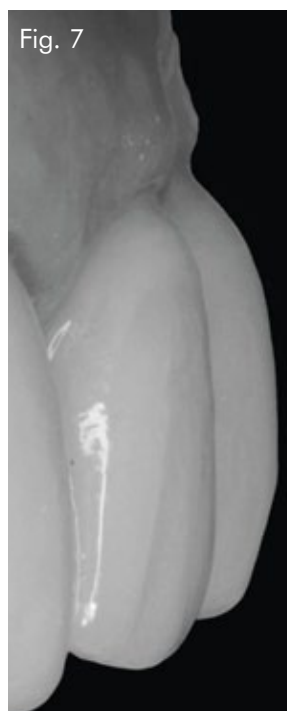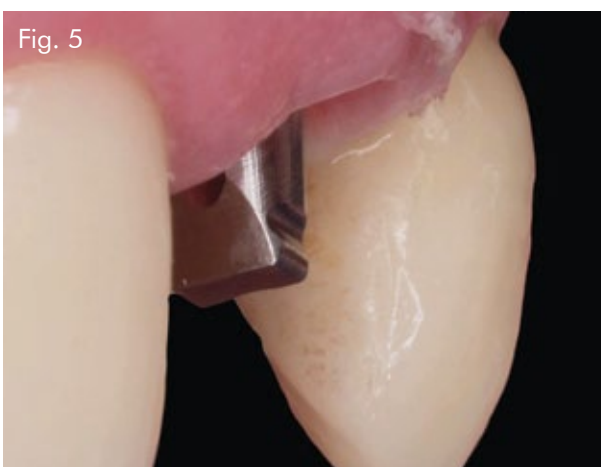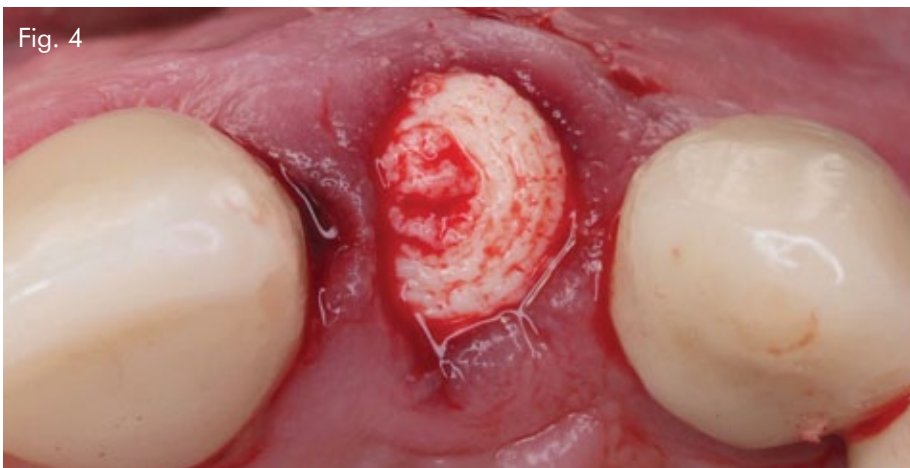
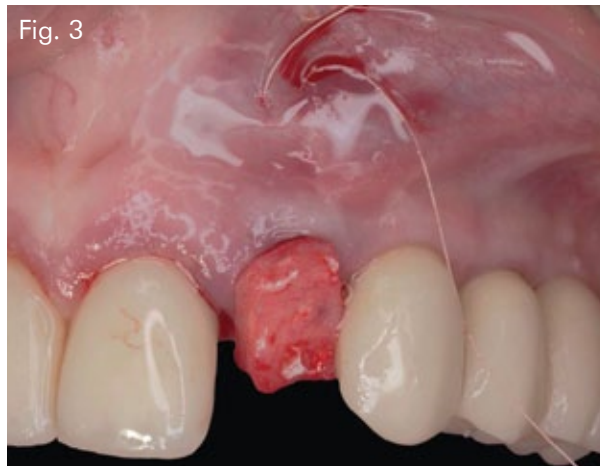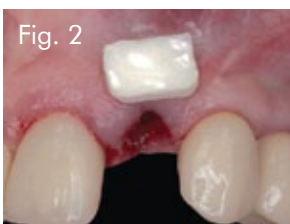
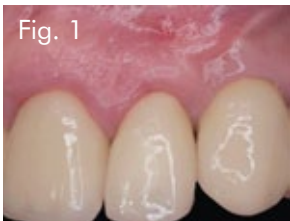
Dr **Roberto Rossi**

DDS, MScD, Private Practice, Genova, Italy.

Clinical Associate Professor,

Department of Periodontology, University of Roma "Sapienza", Italy

Bone substitute: **OsteoBioL® mp3**
Membrane: **OsteoBioL® Derma**



CASE REPORT

Post-extractive immediate implant in the esthetic zone with modification of the gingival biotype with *Derma* membrane

Sex: **Female** | Age: **60**

Fig. 1 Initial situation. The patient has a vertical fracture on 2.2

Fig. 2 After the atraumatic extraction of the tooth, an osteotomy for the 3D positioning of the implant is made. The size of the *Derma* membrane is verified, in order to correct the soft tissue defects

Fig. 3 After a proper hydration, *Derma* is positioned, partially inside the site, as a substitute of the connective tissue

Fig. 4 The alveolus is filled with *Putty*. It is possible to observe the mucogingival correction made with *Derma*

Fig. 5 Cicatrization of the emergency profile after 7 days. There are no signs of post-surgical complications

Fig. 6 After 15 days

Fig. 7 Peri-implant stability, 6 months after the prosthodontic finalization of the case

Documentation provided by
Dr **Antonio Murillo**
Periodontology coordinator, University Alfonso X
Madrid, Spain

Bone substitute: **OsteoBiol® Putty**
Membrane: **OsteoBiol® Derma**

Derma

A XENOGENIC GRAFT FOR SOFT TISSUE AUGMENTATION

Collagenated porcine dermal matrix



Tecnos s.r.l. is an innovative, globally active company that develops, produces and documents premium-quality xenogenic biomaterials by the brands Tecnos® and OsteoBiol®.

Its 20 years of research led to its patent-protected production process that ensures neutralization of antigenic components in order to achieve biocompatibility, while preserving the natural collagen matrix inside the biomaterial.

Tecnos® products comply with highest quality standards such as ISO 10993, ISO 13485 (notified body Kiwa Cermet) and 93/42/EEC (notified body CE 0373).

osteobiol.com

Tecnos® Dental


Via Torino, 23
10044 Pianezza (TO) | Italy
Tel +39 011 9682823
Fax +39 011 9787577
info@tecnos-dental.com

www.osteobiol.com

International Sales & Marketing



Authorized Distributor



MKT-DERO115EN